FROG DISSECTION

EXTERNAL FEATURES

The frog body is divided into two sections: the head and trunk. The frog has no neck so the trunk follows immediately behind the head. The frog has three eyelids: the fleshy upper eyelid, the thinner lower eyelid, and the transparent nictitating membrane. The nictitating membrane is drawn up over the eye when the frog is underwater. Its function is to compensate for the different refractive index water has compared to air; this allows the frog to see clearly under water. The large circular disc just posterior to the eye is the tympanum. This thin membrane is functionally equivalent to the human eardrum in that it transmits sound waves mechanically to one bone (there are three in mammals) which in turn transmits the mechanical energy to the nervous system receptor. The cloaca services a common urogenital opening to release the gametes of both sexes (egg and sperm) and also to void waste products.

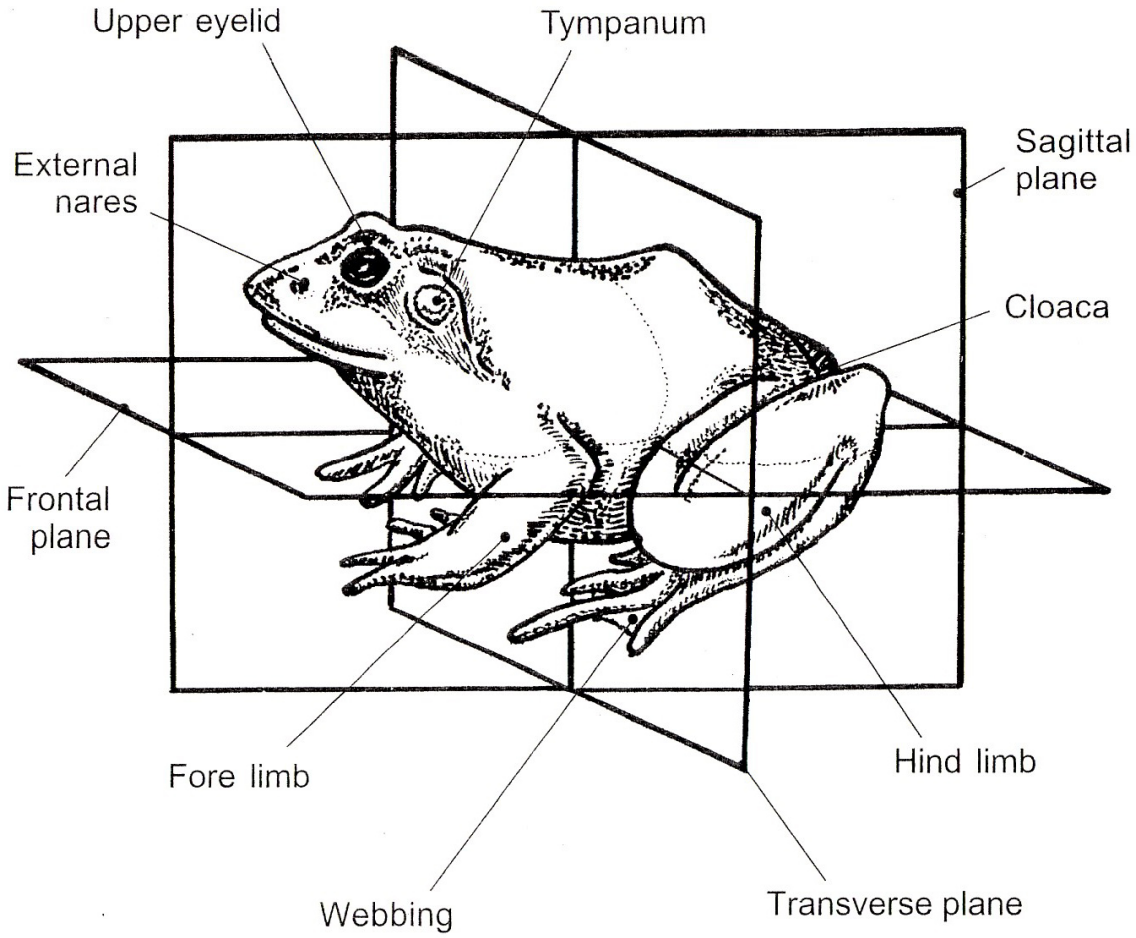

Mouth Structures

With a wooden stick hold the mouth open. It may be necessary to cut the jaw bones apart with scissors in order to see all of the mouth details. With the jawbone cat at the point where both of them come together in the caudal end of the mouth, the top portion of the head can be folded back. Identify the structures indicated on the drawing below.

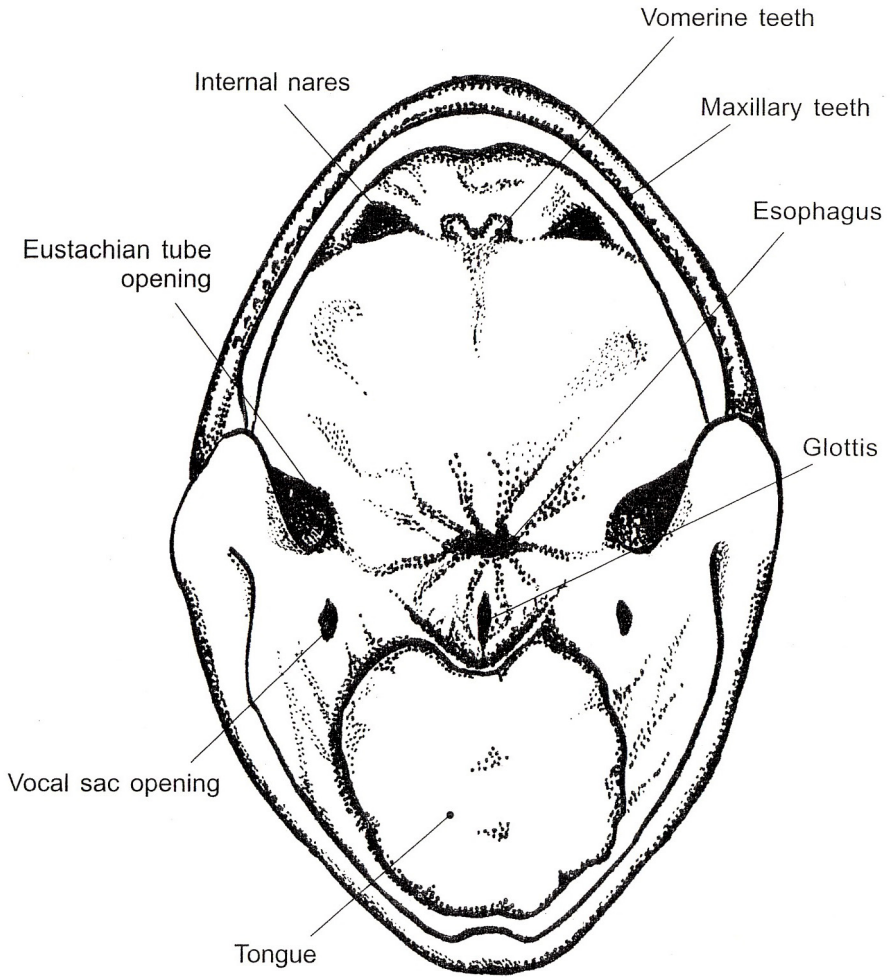

Maxillary Teeth - run your finger along the upper jaw and feel these small sharp teeth. These teeth are not used for chewing but only to hold the frog's prey firmly. Frogs swallow their prey whole.

Vomerine Teeth = These two sets of teeth located in the cranial portion of the upper jaw. Not for chewing. These teeth are pointed inward to prevent prey from escaping.

Tongue - This muscular structure is attached on the front end to the jaw (unlike humans) so that the tongue can be flipped out to snare prey.

Glottis - A small rounded structure with a vertical slit found just caudal to the tongue. This is the air passage to the lungs.

Esophagus - In the center of the mouth this passageway is to pass food from the mouth to the stomach.
Eustachian tubes - On both sides of the upper jaw these openings serve to equalize air pressure on both sides of the tympanum. Humans also have these.
Internal Nares - At the cranial end of the upper jaw these two openings allow the frog to breathe with its mouth closed.
Vocal Sac Opening - Found in male frogs only, these are small slits on either side, distally of the glottis. These passages allow the male frog to fill his vocal sac with air which allows him to produce his mating call.

MAJOR MUSCLES OF THE FROG

1. Remove the skin of the frog by making shallow cuts around the wrists and ankles of your frog. Then make the cuts outline in the figure below.

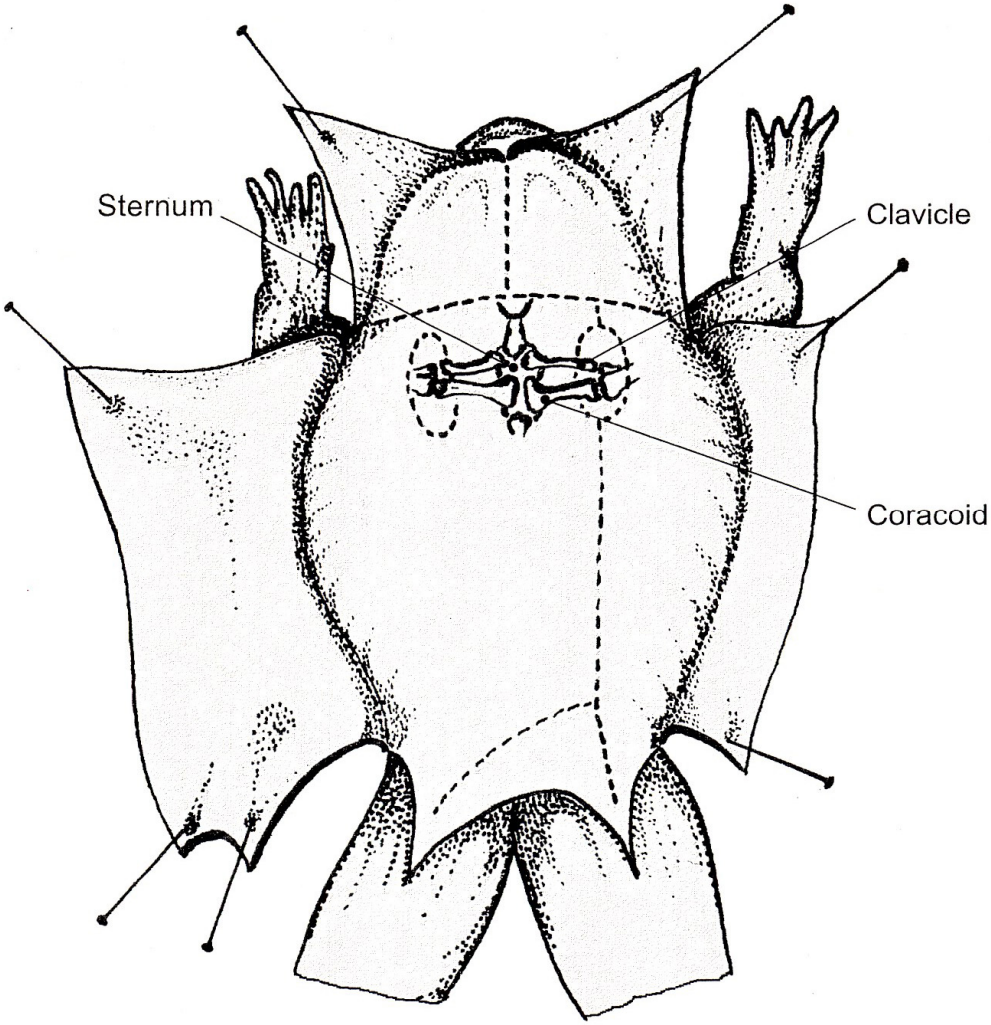

IDENTIFY THE DORSAL MUSCLES OF THE FROG SHOWN BELOW

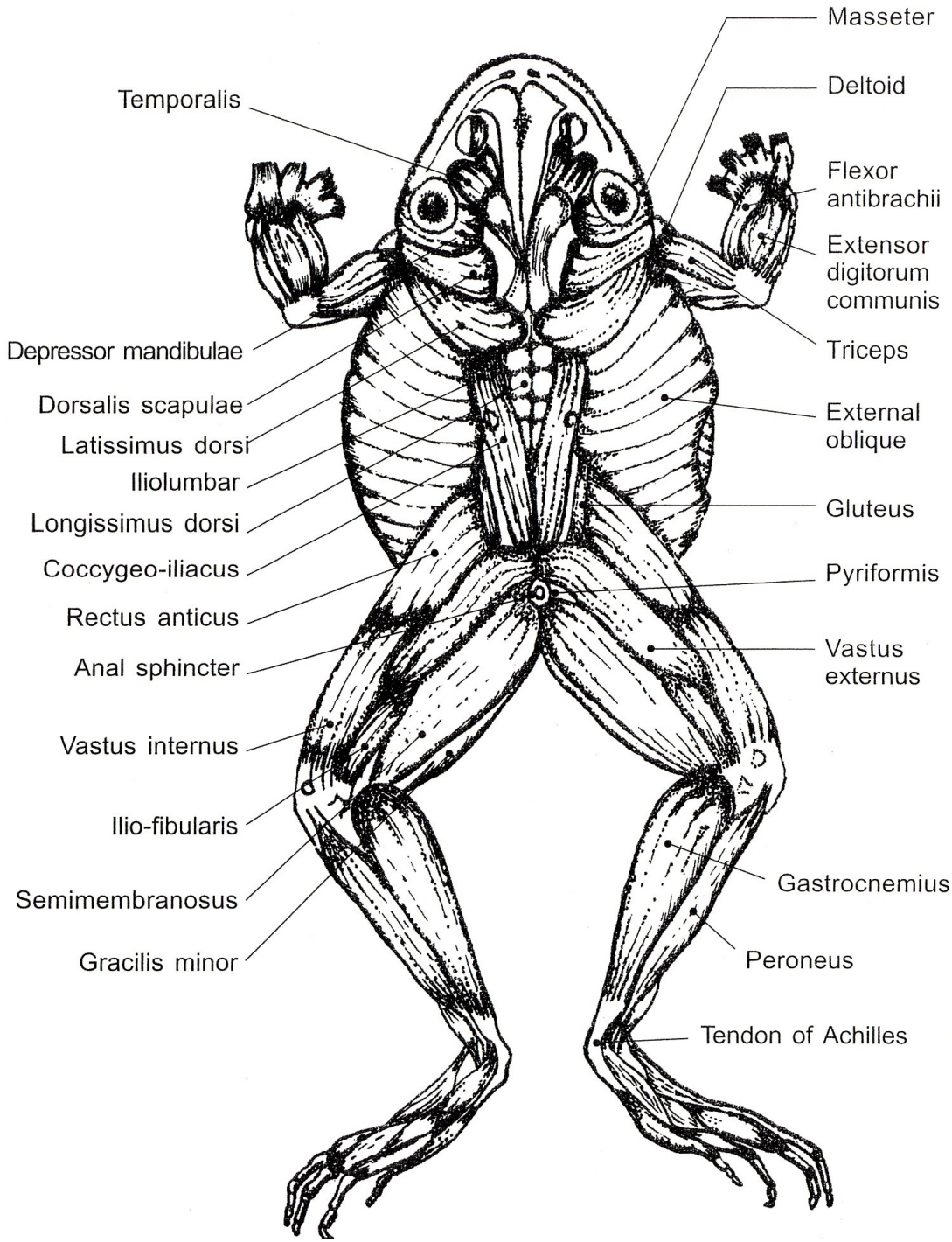

IDENTIFY THE VENTRAL MUSCLES OF THE FROG SHOWN BELOW

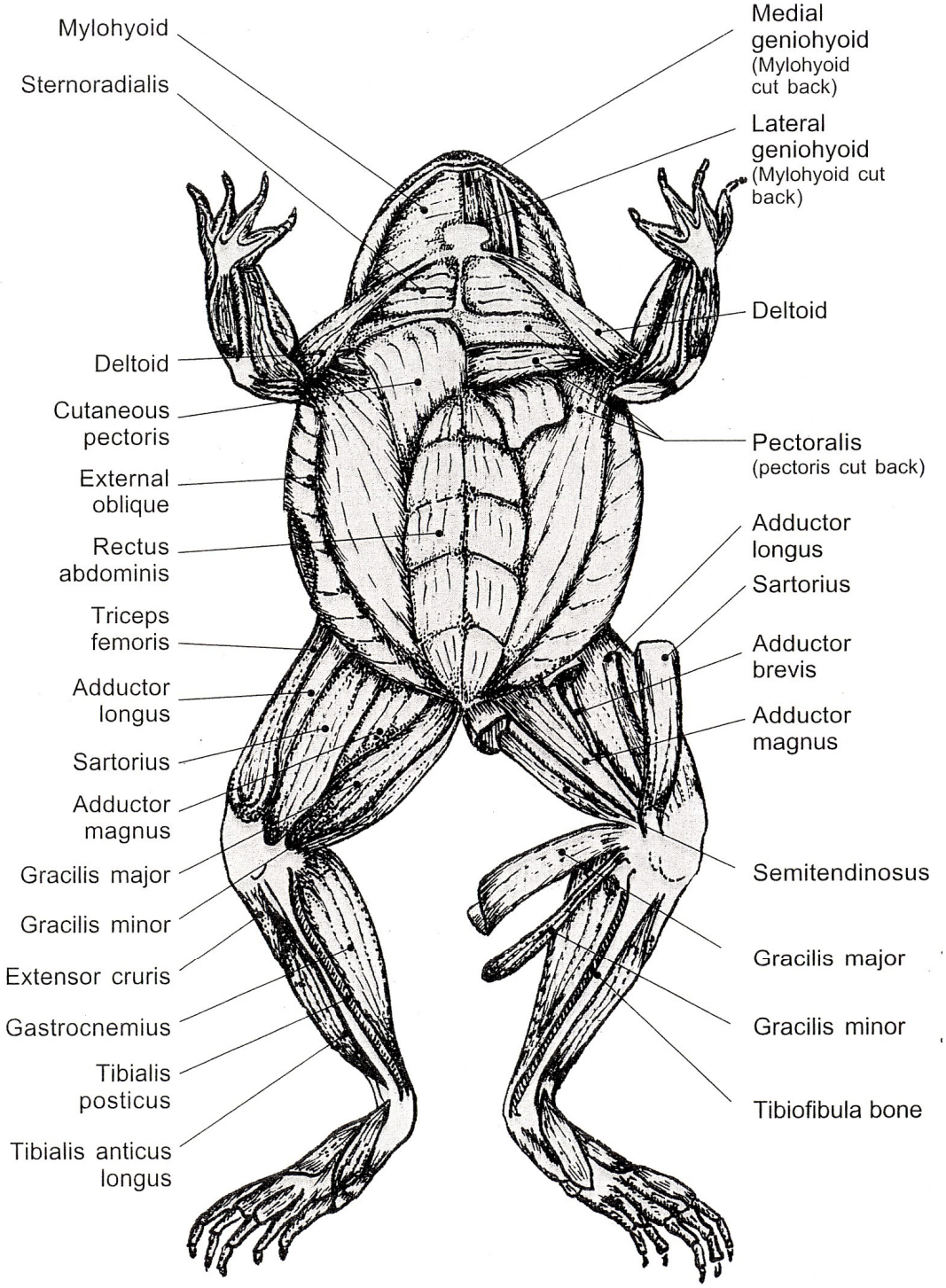

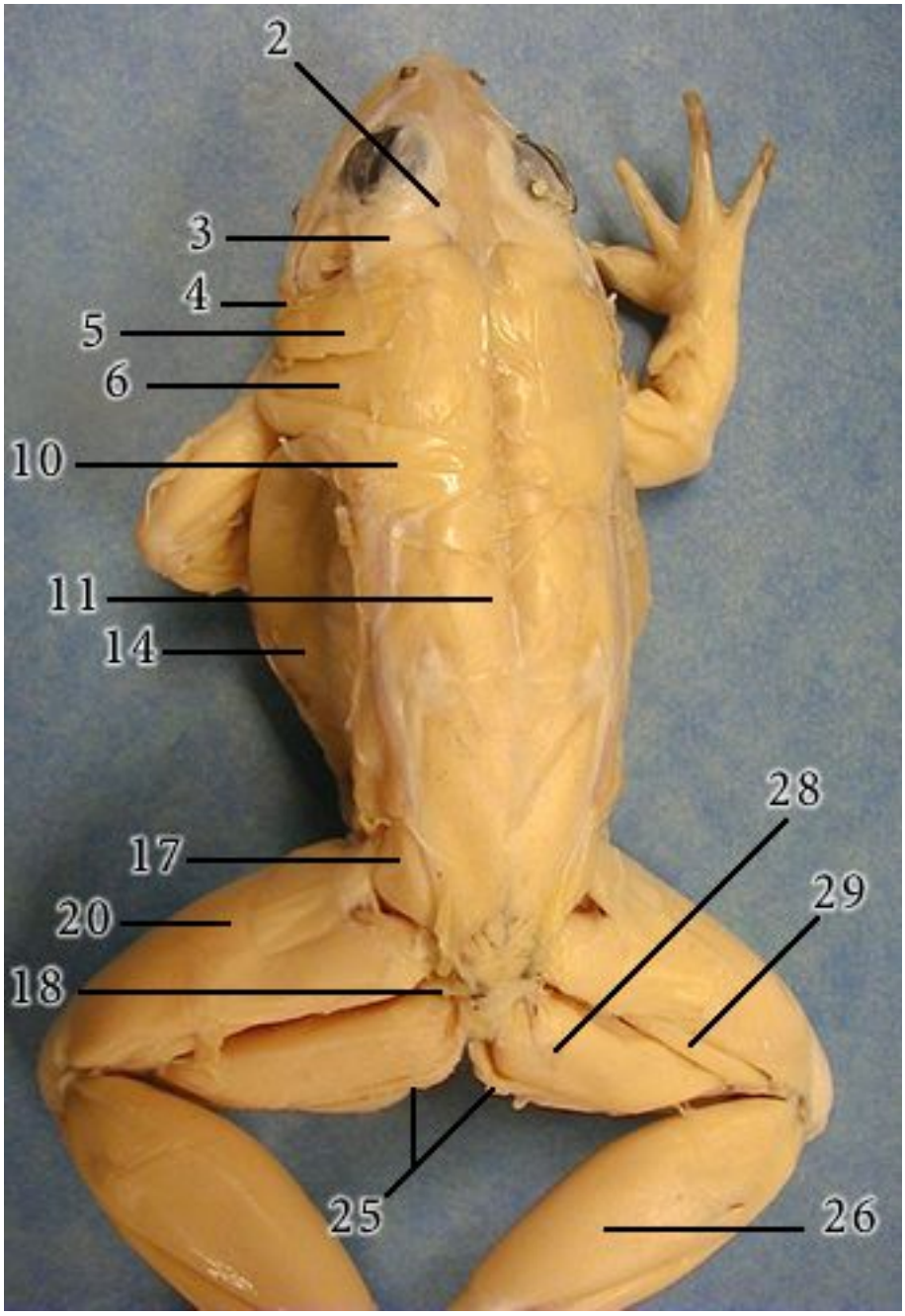

2 - pterygoideus
3 - temporal
4 - masseter
5 - depressor mandibularis
6 - dorsal scapulae
10 - latissimus dorsi
11 - longissimus dorsi
14 - external oblique abdominis
17 - gluteus
18 - piriformes
20 - triceps femoris
25 - gracilis minor
26 - Gastrocnemius
28 - semimembranosus
29 - biceps femoris

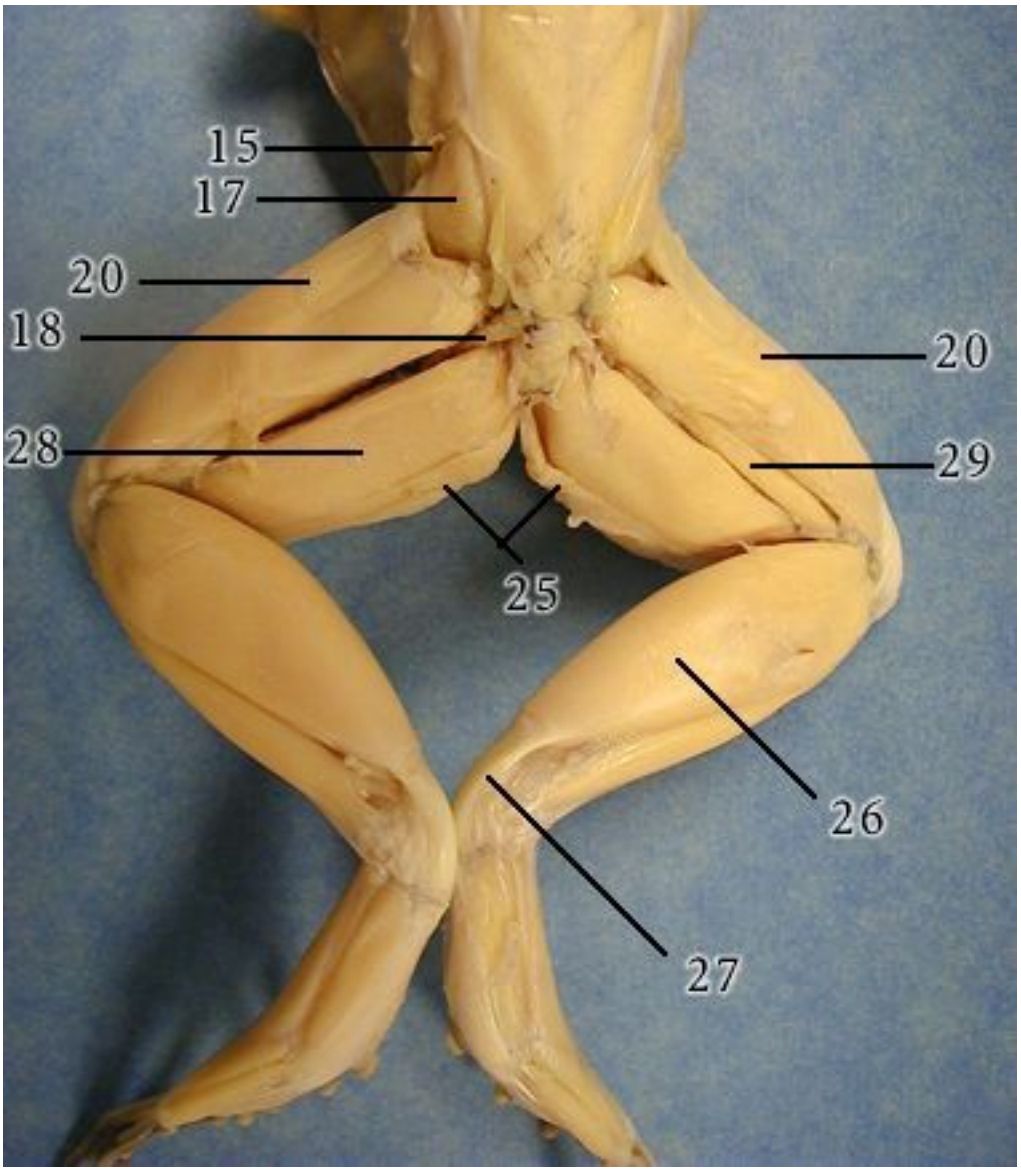

15 - cutaneous abdominis
17 - gluteus
18 - piriformis
20 - triceps femoris
25 - gracilis minor
26 - gastrocnemius
27 - Achilles tendon
28 - semimembranosus
29 - biceps femoris

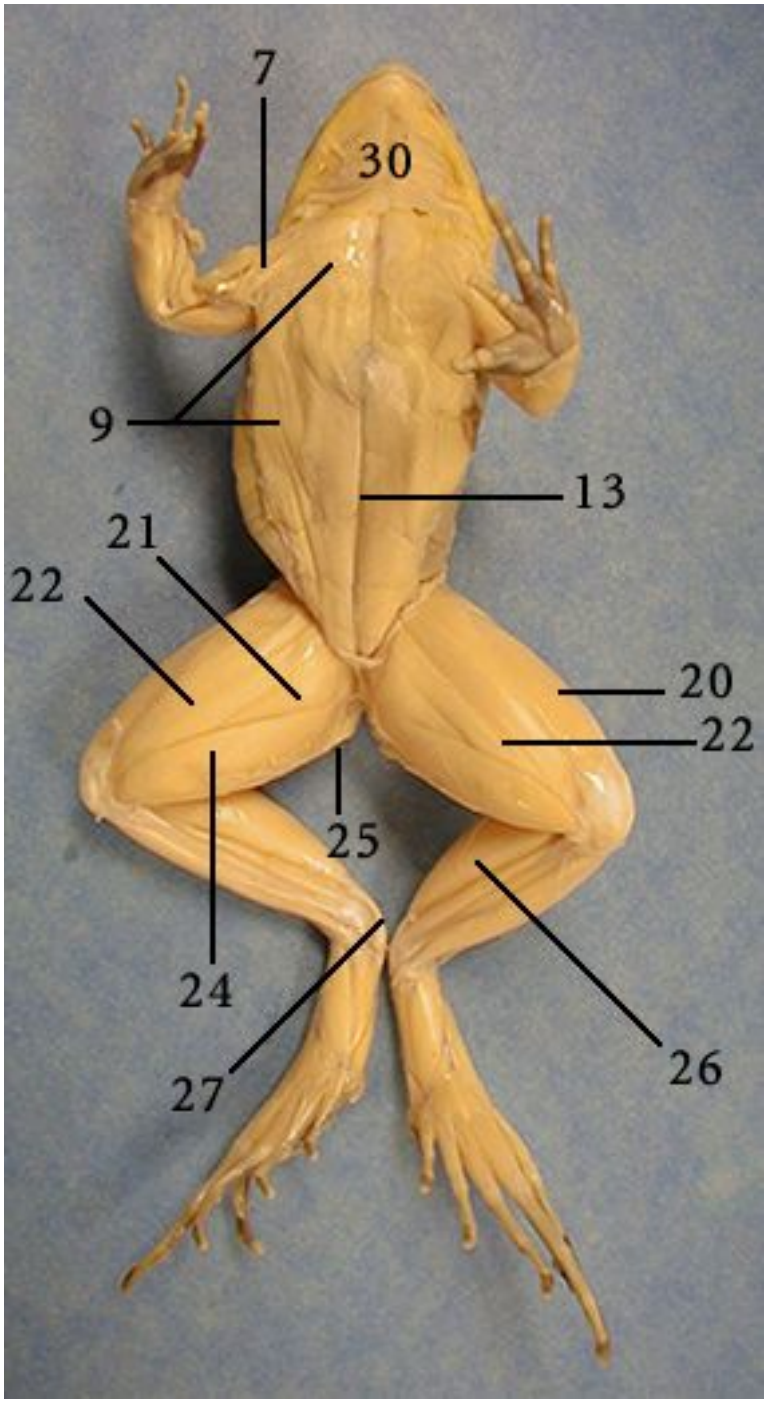

7 - deltoid
9 - pectoralis
13 - linea alba
20 - triceps femoris
21 - adductor magnus
22 - sartorius
24 - gracilis major
25 - gracilis minor
26 - Gastrocnemius
27 - Achilles tendon
30 - mylohyoid

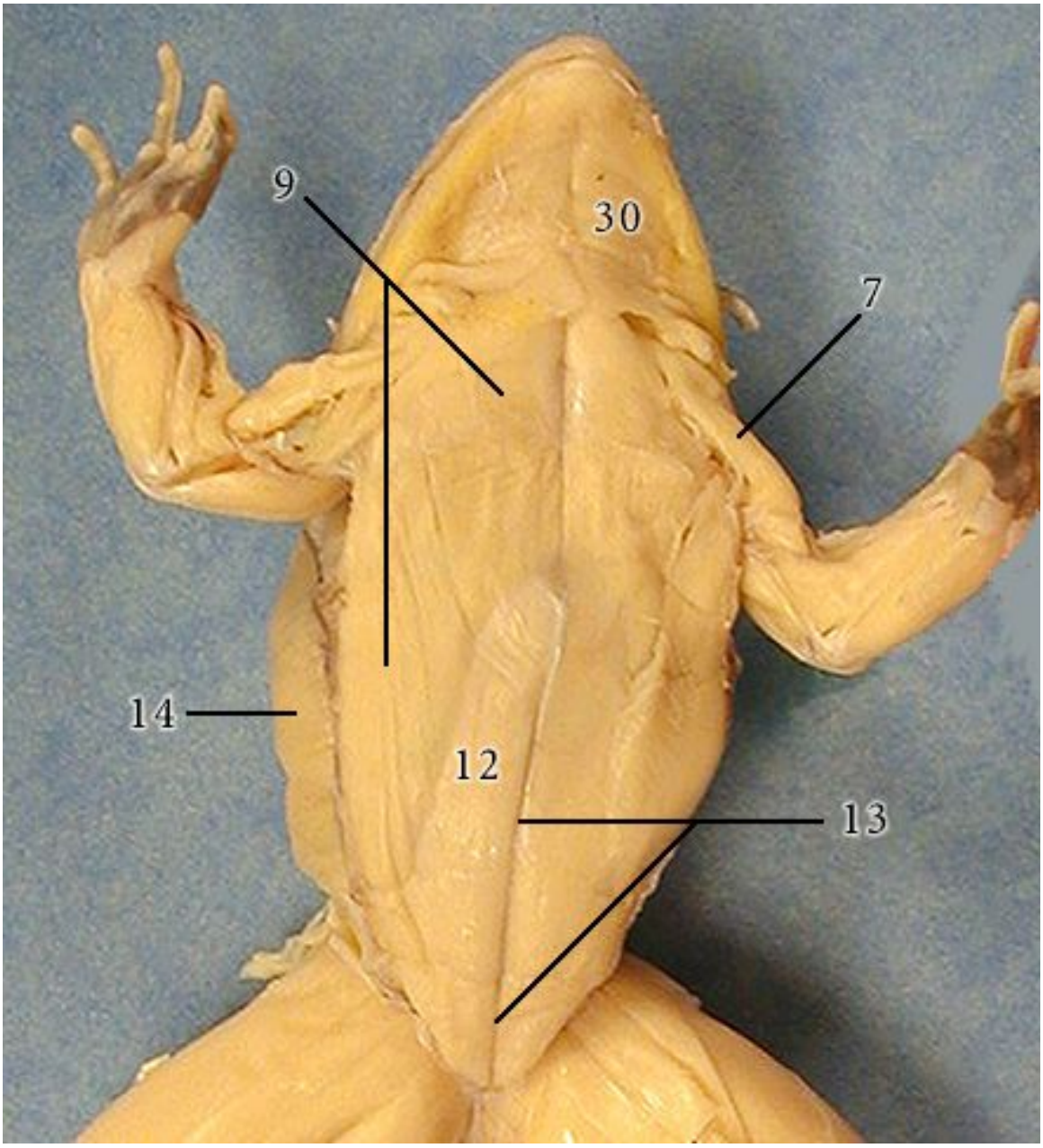

7 - deltoid
9 - pectoralis
12 - rectus abdominis
13 - linea alba
14 - External oblique
30 - mylohyoid



12 - rectus abdominis
14 - external oblique
19 - Adductor longus
20 - triceps femoris
21 - adductor magnus
22 - sartorius
23 - semitendinosus
24 - gracilis major
26 - gastrocnemius
28 - semimembranosus

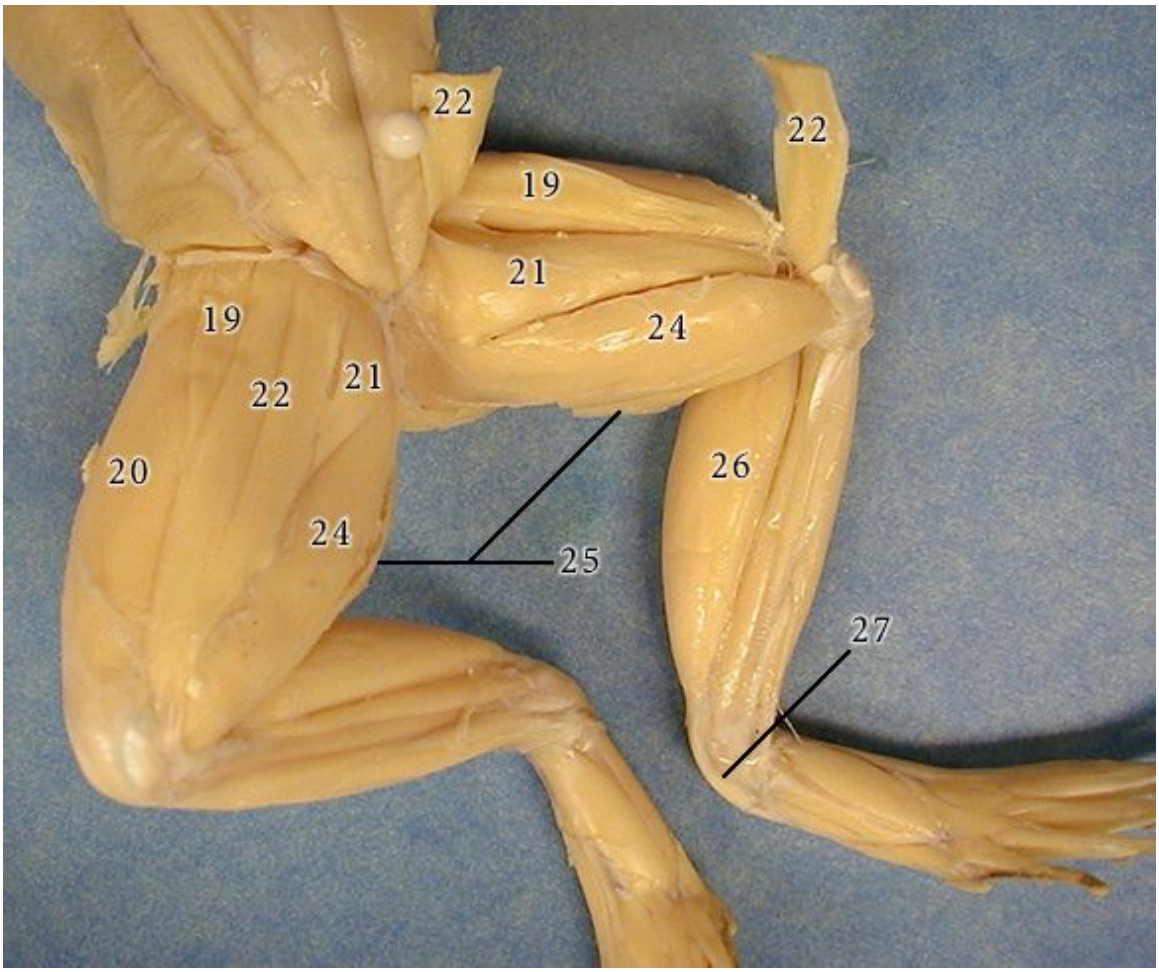

19 - adductor longus
20 - triceps femoris
21 - adductor magnus
22 - sartorius
24 - gracilis major
25 - gracilis minor
26 - gastrocnemius
27 - Achilles tendon



2 - pterygoideus
4 - masseter
5 - depressor mandibularis
6 - dorsalis scapulae
7 - deltoid
10 - latissimus dorsi



4 - Masseter
5 - depressor mandibularis
6 - dorsalis scapulae
10 - latissimus dorsi

IDENTIFY THE BONES OF THE FROG SKELETON SHOWN BELOW

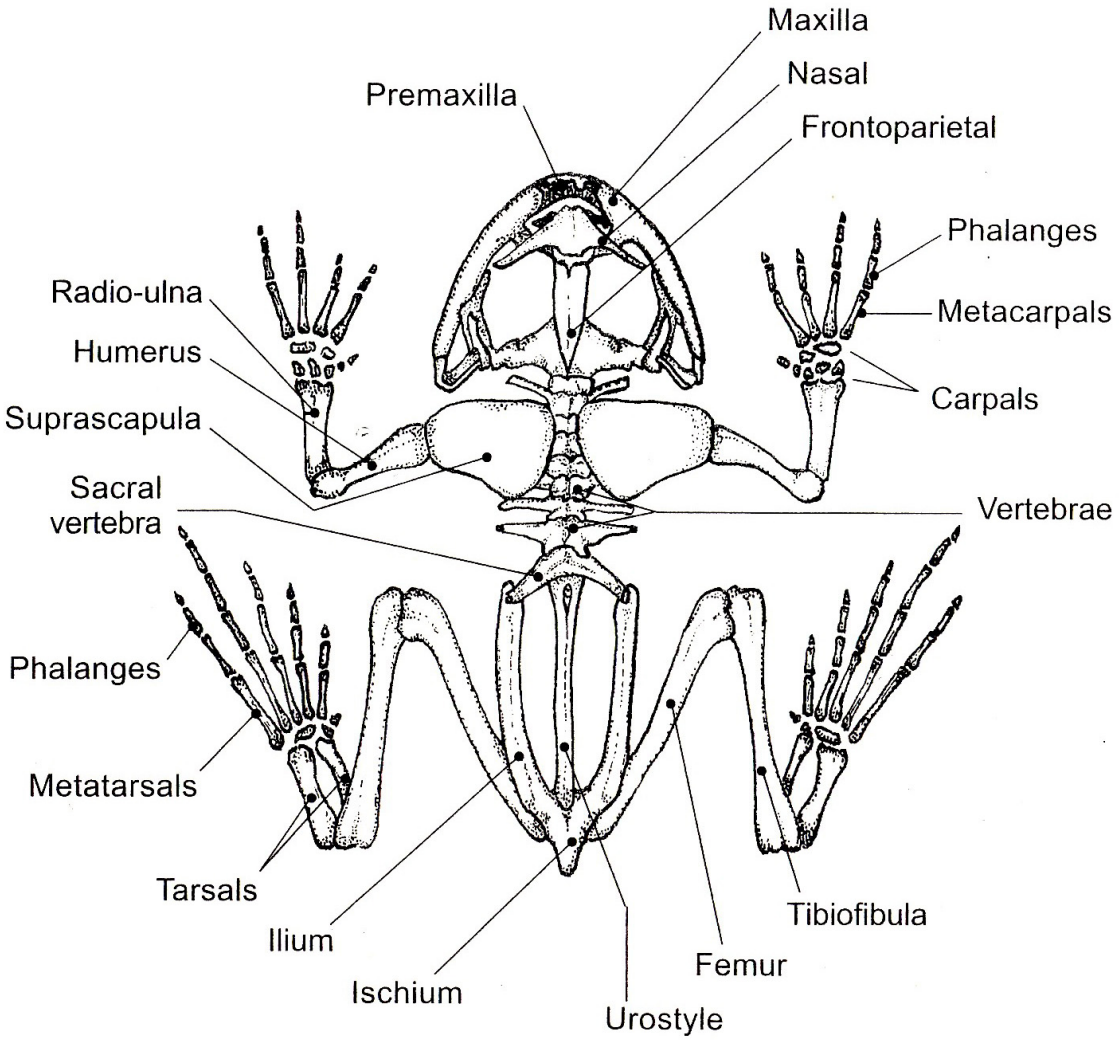

INTERNAL ANATOMY - STEPS IN DISSECTION

1. Refer to the figure on page 3 of this handout to open the body wall. Be sure you make your first incision to one side of the midline, starting from the caudal end cutting to the pectoral girdle. Make these cuts as shallow as possible in order to avoid damaging the internal organs. Use the blunt probe to go underneath the body wall.
2. In order to view the heart and lungs it is necessary to remove the pectoral girdle. Grasping the sternum with forceps cut the clavicle and coracoid bones at the joint where these bones join the scapula and humerus, then lift out the pectoral girdle. Before you do this examine the frog skeleton model in lab so you know what you are cutting.
3. The exposed organs are wrapped in the peritoneum membrane except for the heart which is wrapped separately in the pericardial sac. In mammals the thorax is separated from the abdominal cavity be the diaphragm. The frog does not have a diaphragm.
4. If your specimen is a female, a large portion of the coelom (body cavity) may be filled with black and cream colored eggs. When you remove the eggs you will also remove the ovaries. Be sure to examine a female that does not have eggs.

DIGESTIVE SYSTEM

Be able to recognize the structures illustrated and listed below

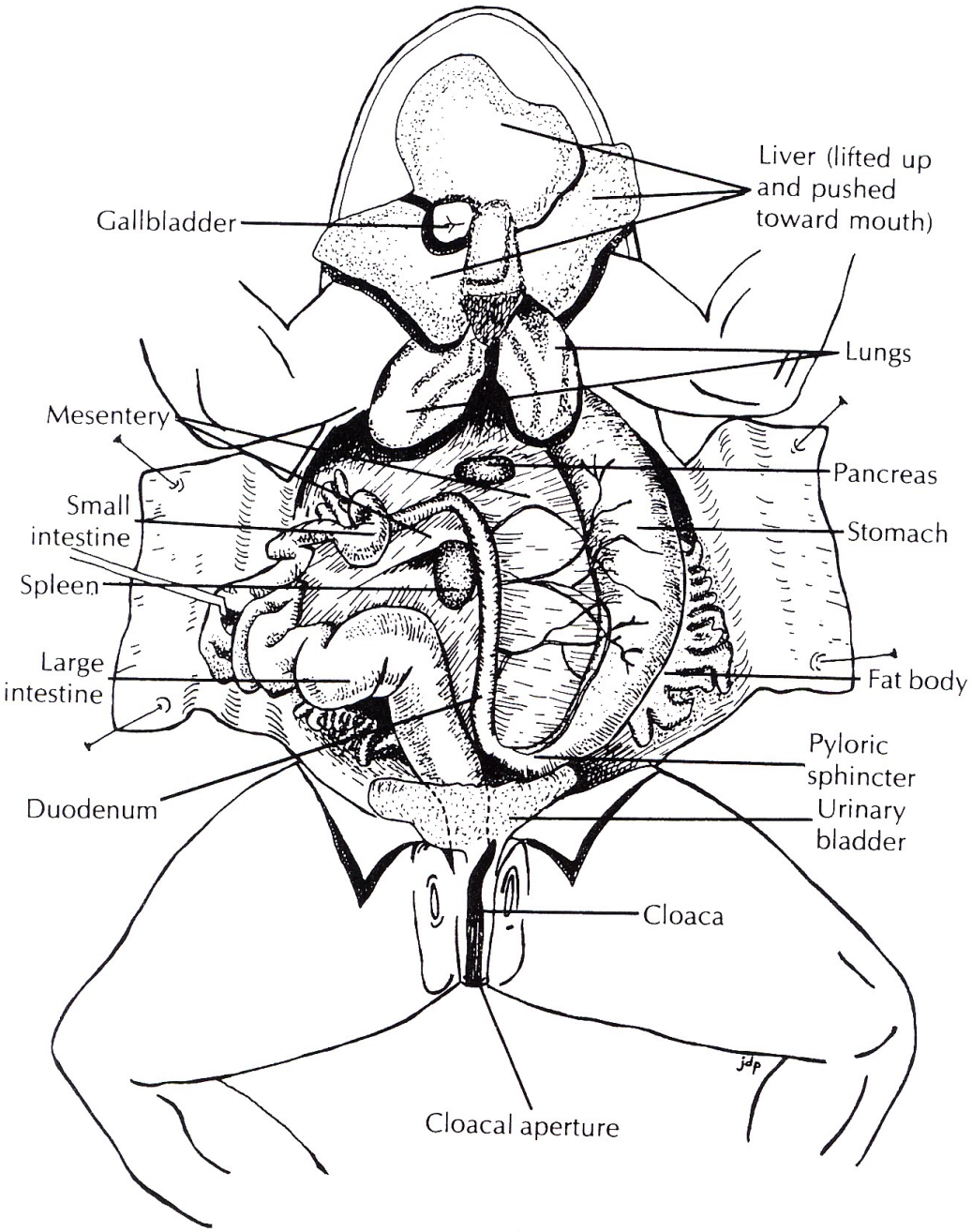

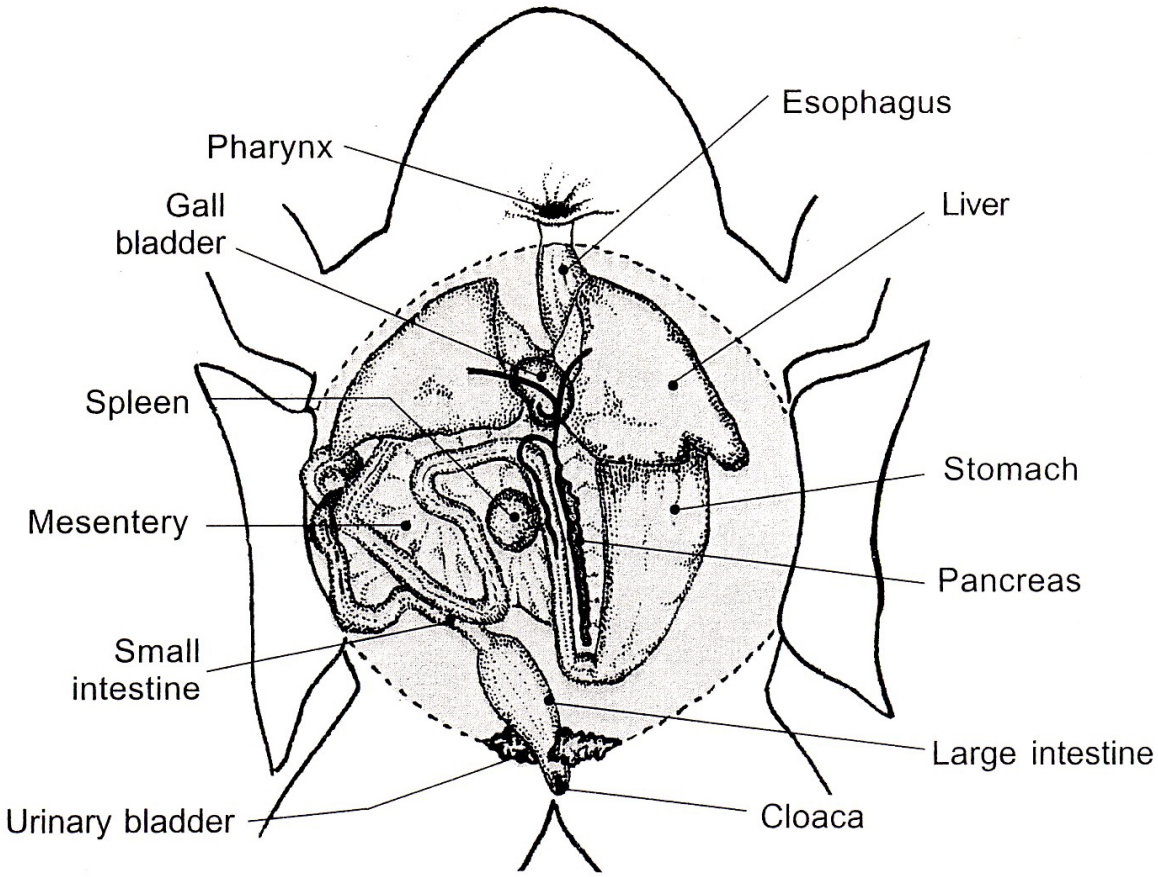

Digestive organs.

DIGESTIVE SYSTEM

1. **Liver** consists of three reddish lobes. The liver surrounds the caudal sides of the heart. The liver is a vital organ which helps purify blood and store glycogen. In addition the liver secretes bile which breaks up fats in the small intestine.

2. **Gall Bladder** stores bile. It is located between the left and right lobes of the liver and is greenish in color (caused by the bile).

3. **Stomach** is found under the left lobe of the liver. Leading into the stomach cranially is the esophagus.

4. **Small Intestine** is attached at the caudal end of the small intestine. The small intestine is attached to the posterior wall of the abdomen by a transparent membrane called the **mesentery.**

5. Large Intestine is the enlargement at the end of the small intestine. It absorbs water from the fecal material inside.

6. **Cloaca** is located at the caudal end of the large intestine. It is the space where the digestive and urogenital systems meet.

7. **Spleen** is located within the coils of the small intestine. This brownish, round organ, is actually a part of the circulatory system in that it filters red blood cells.

8. **Pancreas** is located between the small intestine and the stomach and is an elongated yellow organ. The pancreas is a gland which secretes pancreatic enzymes and the hormone insulin.

9. **Fat Bodies** are a cluster of oblong, yellow lobes attached to the cranial end of each kidney. Frogs do not store fat under the skin like humans. These fat bodies are used for storage of food used during hibernation or periods of breeding.

RESPIRATORY SYSTEM

The two **Lungs** are located one on each side of the heart (slightly dorsal). Trace the cranial ends of the lungs to located the two bronchi which lead to the glottis in the mouth. Frogs have simple, single chambered lungs which are not very efficient. Frogs of the genus Rana do most of their respiration across the skin which is highly moisturized with lots of blood vessels. The mouth and buccal cavity (lies ventral to the jaw at the bottom of the mouth) of the frog are also moisturized and highly vascularized for respiratory purposes.

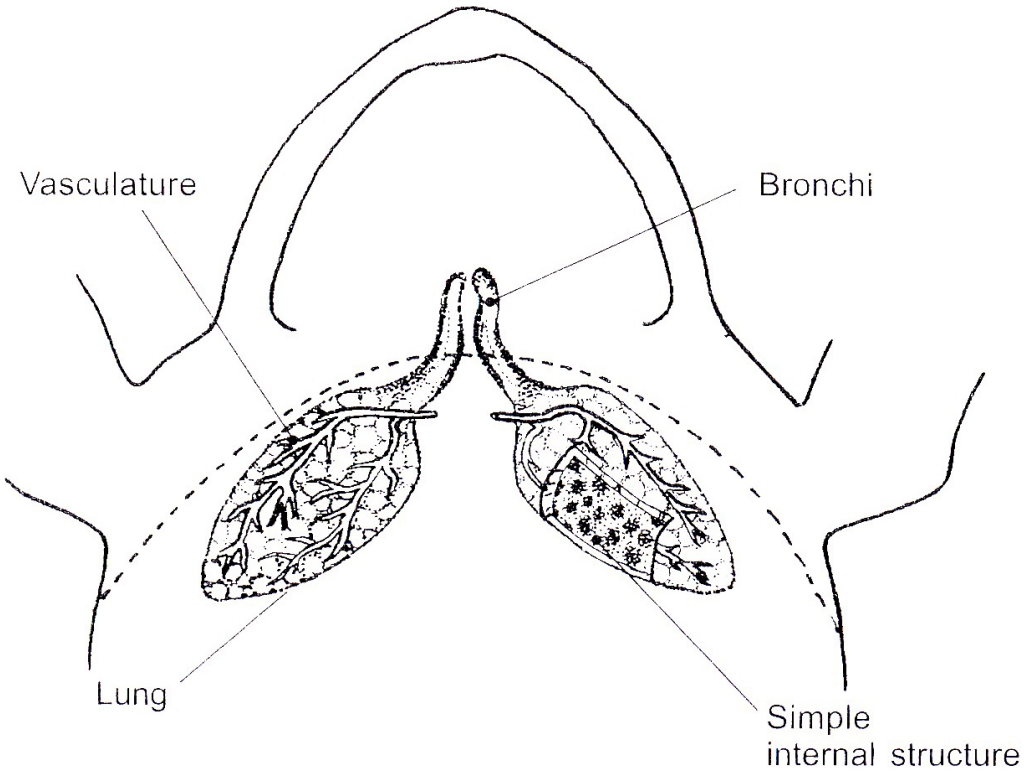

THE HEART

The frog heart has three chambers: the **Ventricle**, the right **atrium** and the left **atrium.** This structure allows some mixing of the deoxygenated venous blood with the oxygenated arterial blood, but studies have shown that very little mixing occurs. Examine as many parts of the heart (shown on the illustration below) as you can without further dissection. Do not remove the heart from the frog.

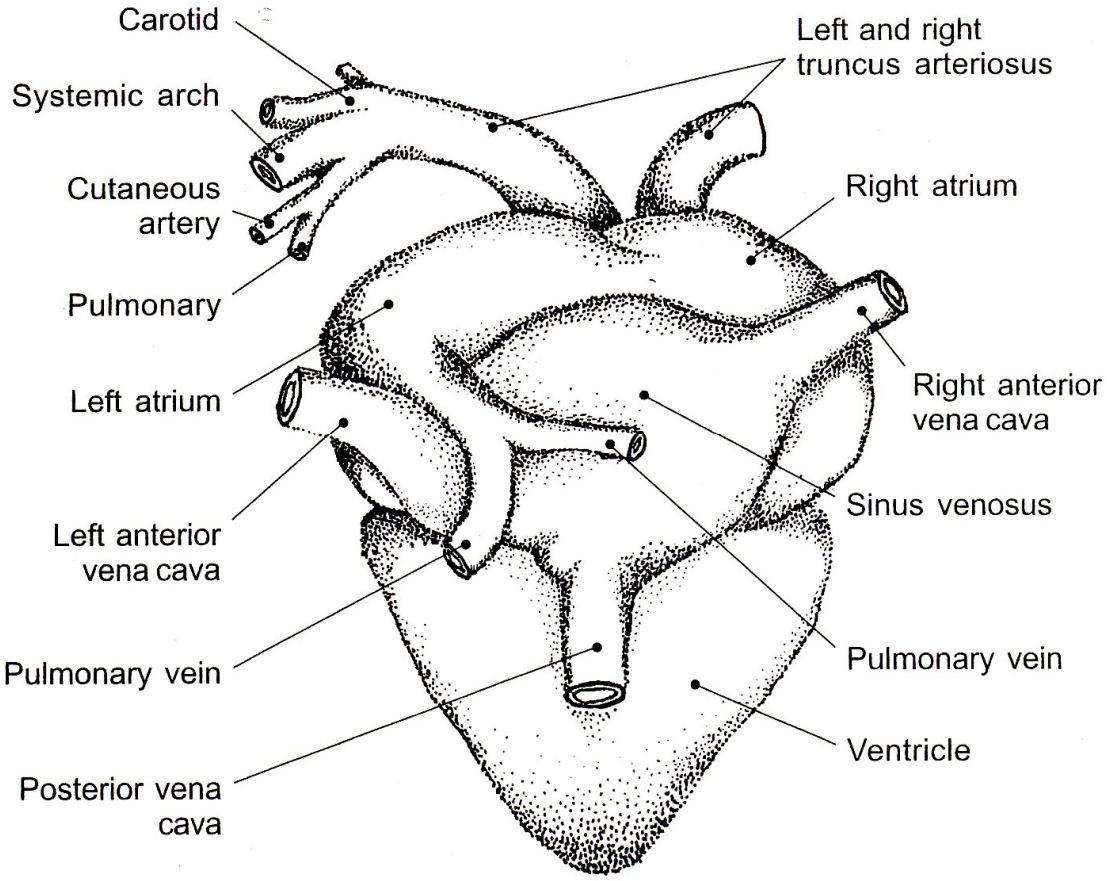

The venous blood enters the **sinus venosus** from the cranial and caudal **vena cava**. From there it enters the right atrium after a contraction. At the same time blood returning from the lungs via the pulmonary veins enters the left atrium. When both atria are full they contracted forcing the blood into the ventricle. The ventricle contracts forcing the oxygenated blood from the left atrium into the truncus arteriosus and the unoxygenated blood from the right atrium into the pulmocutaneous arch which leads to the skin and lungs for oxygenation. This latter blood flow occurs after the ventricle contracts.

THE MAJOR ARTERIES

Identify as many of the arteries illustrated below as you can without further dissection. Isolate individual arteries using the blunt probe. Do not cut or remove anything.

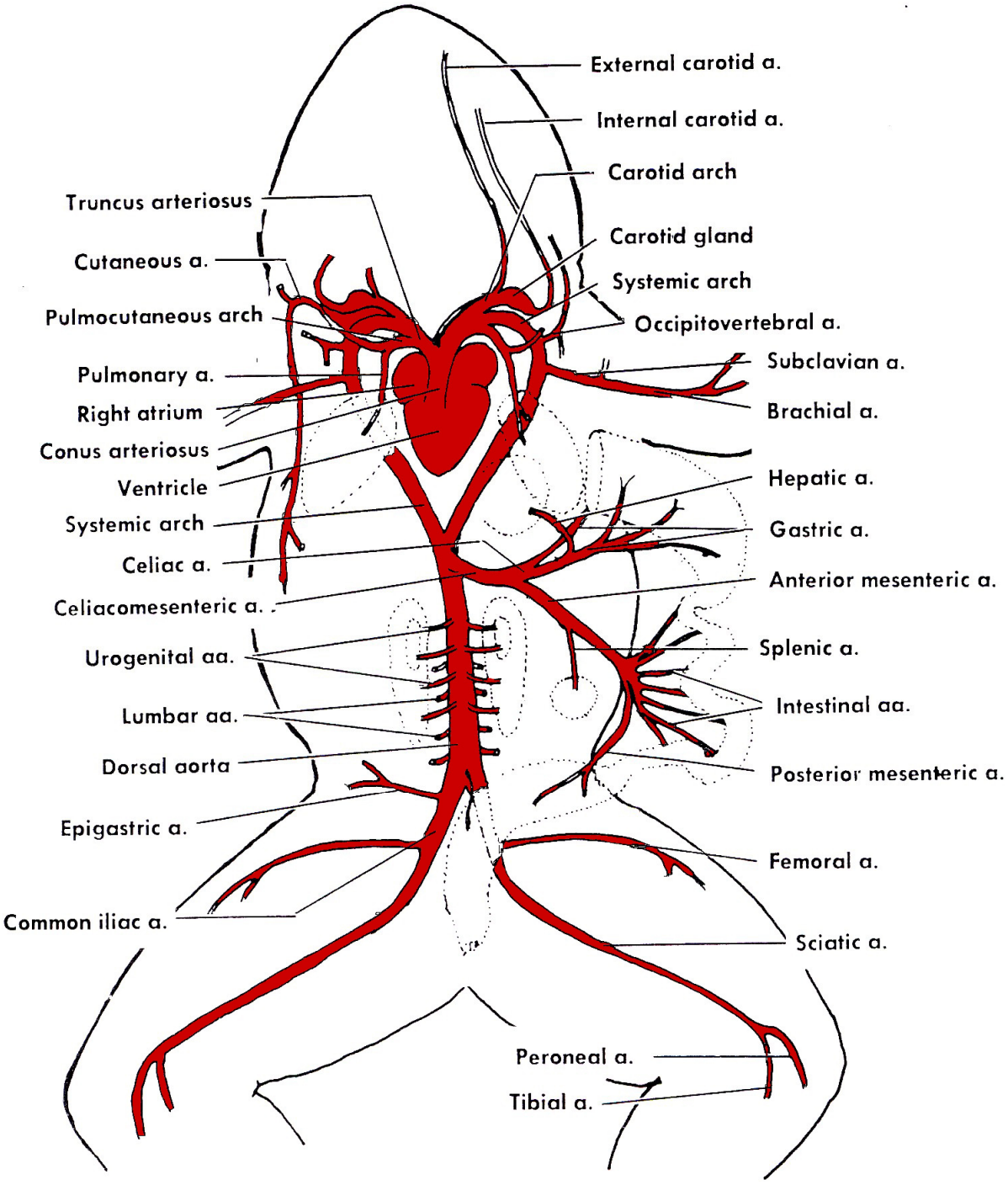

THE MAJOR VEINS

Identify as many of the veins illustrated below as you can without further dissection. Isolate individual veins using the blunt probe. Do not cut or remove anything.

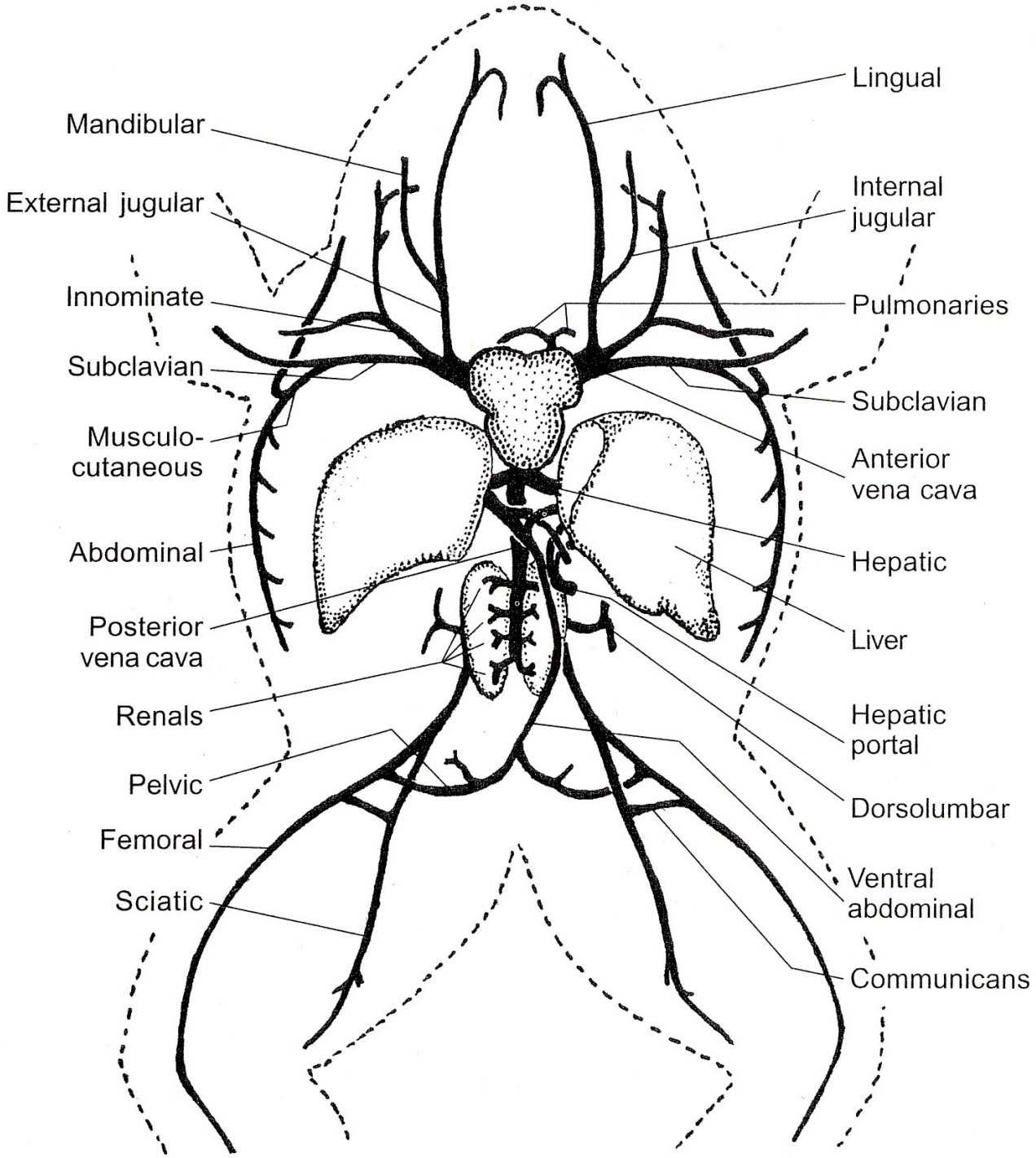

THE UROGENITAL SYSTEM - is actually two separate systems; the reproductive system and the urinary system that are closely allied and in the same body area.

FEMALE REPRODUCTIVE SYSTEM

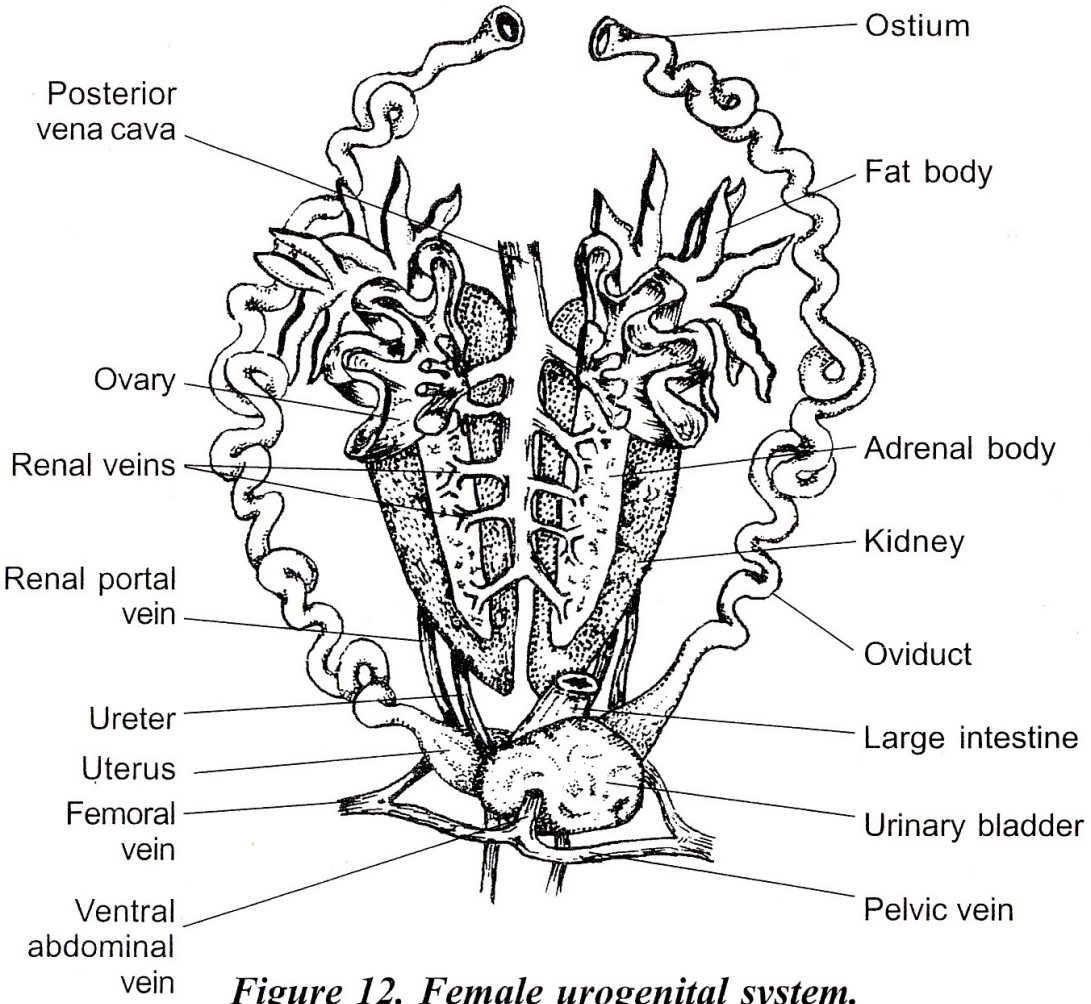

Figure 12. Female urogenital system.

1. **Ovaries** - are often full of eggs which had to be removed in the beginning of the dissection. If they weren't removed they will be found ventrally and cranially from the kidneys. There are two ovaries, each associated with a kidney. The ovaries produce the female gametes (eggs) and female sex hormones.

2. **Oviducts** - are the long, whitish tubes through which the eggs travel in order to pass out of the body. The eggs are flushed into the oviduct by coelenic fluid flow and pass through the oviduct by ciliary movement of the inner oviduct cells.

3. **Uterus** - these are the caudal enlargements of the oviducts which open into the **cloaca.**

MALE REPRODUCTIVE SYSTEM

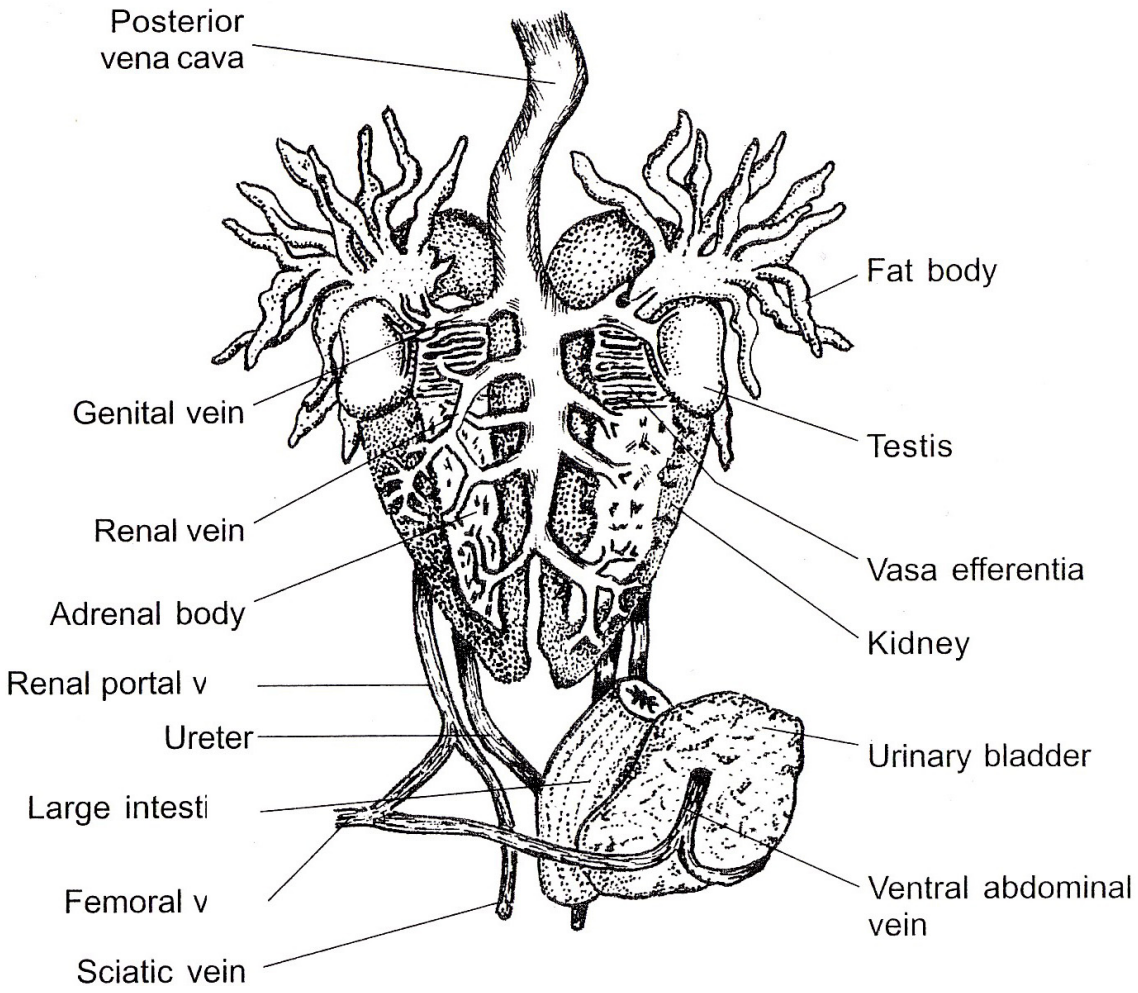

1. The **testes** are small cream colored and pear shaped organs that are located above the cranial end of each kidney. The testes produce **sperm** the male gamete cells. From the testes the sperm travels to the kidneys via the small **vasa efferentia** (you wont be able to see these without a hand lens). From the kidney the sperm travels to the bladder with the urine.

THE URINARY SYSTEM

1. The **Kidneys** are elongated brownish-red organs which lie dorsally on either side of the midline. The kidney removes body wastes from the blood, producing urine.

2. The **ureters** carry urine and in males sperm, from the kidneys to the cloaca.
3. **Urinary Bladder** is a thin bilobed sac at the caudal end of the body cavity and is ventral to the cloaca. Find where the two lobes join to the cloaca. Urine is stored in the bladder for use as a reservoir of water which can be extracted in time of drought.

THE BRAIN

The brain can be exposed by removing the fronto-parietal bone (top of the cranium). To do this make two cuts with a pair of strong scissors on either side of the cranium, cranially to the nostrils. Then by pressing in on both lateral sides of the head with one hand (loosen the skull bones) remove the frontoparietal bone with forceps. The brain is now exposed. Identify any of the parts below that you can find.